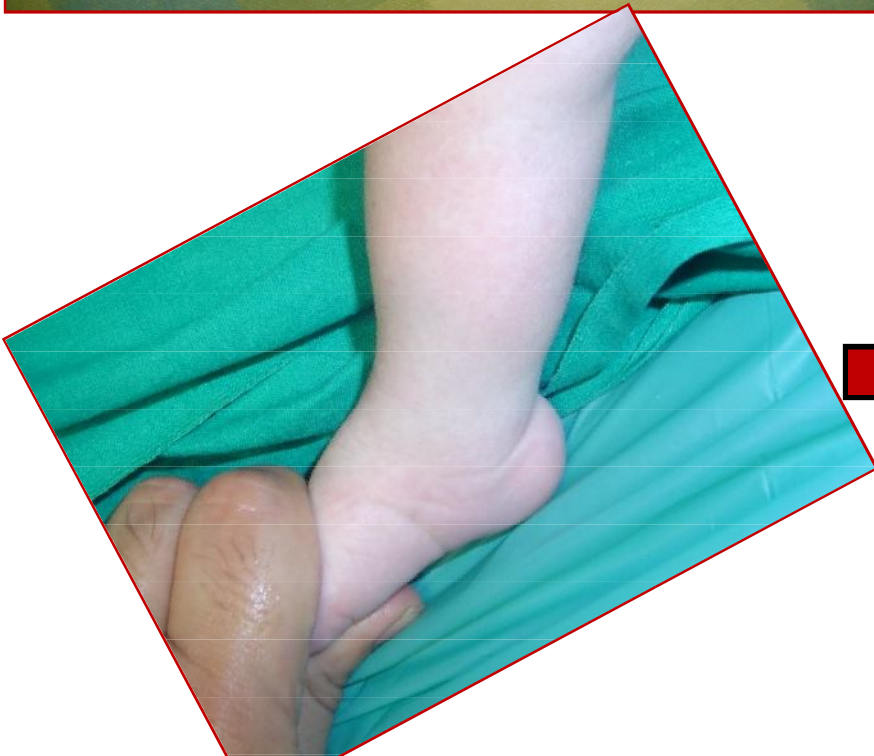
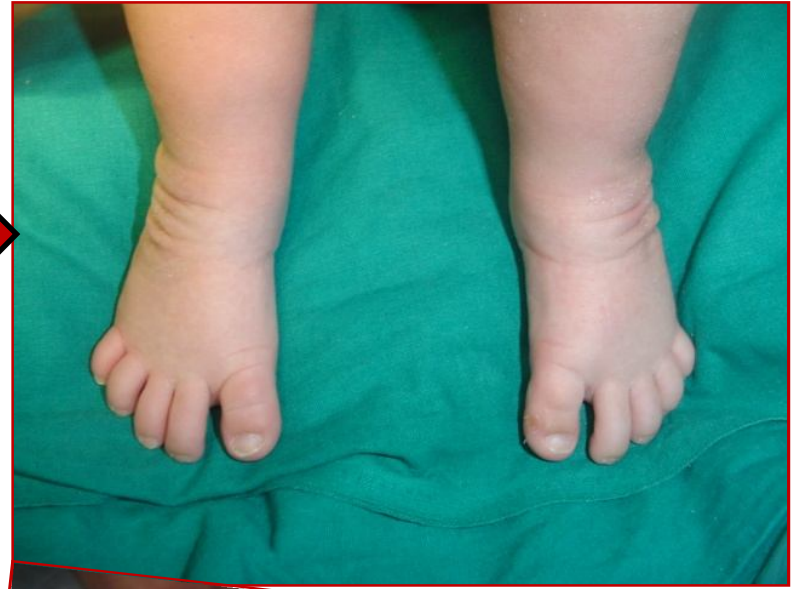
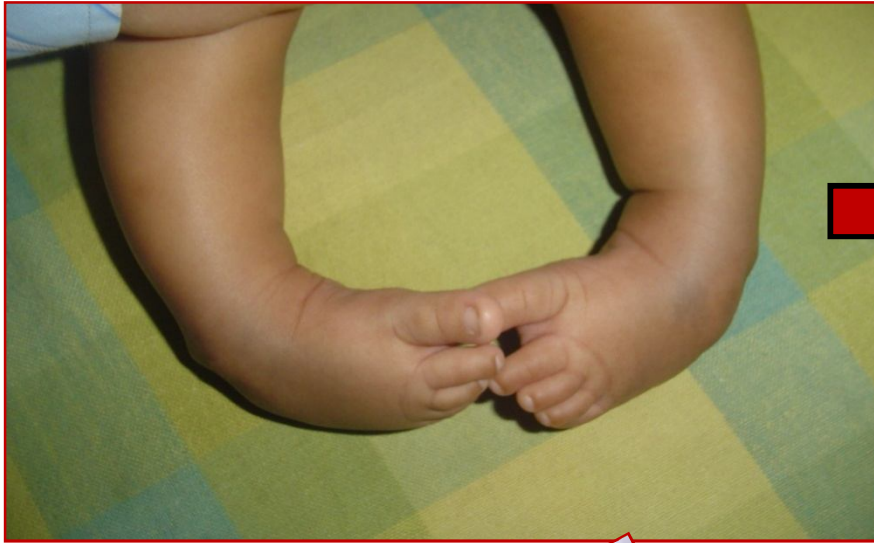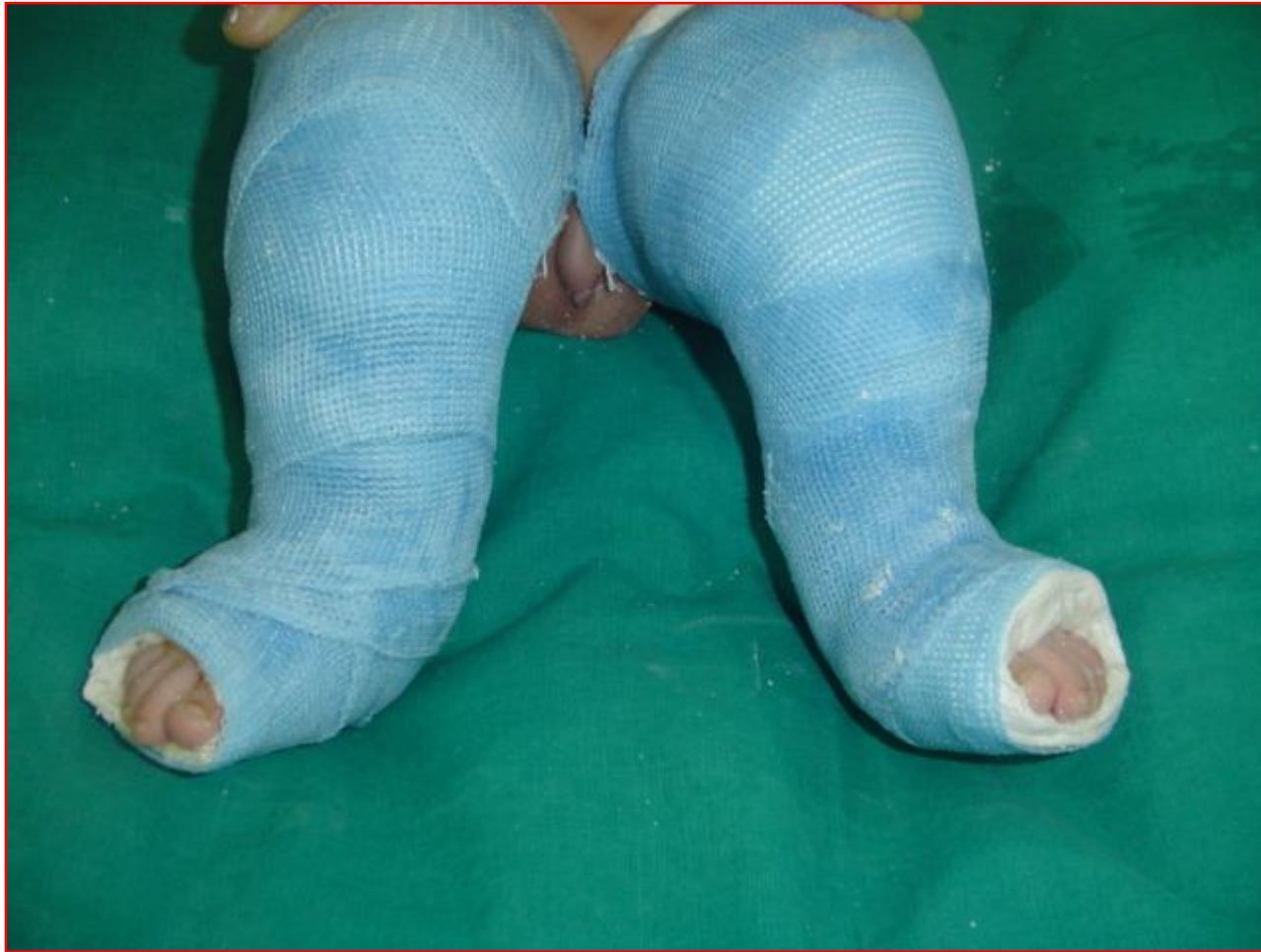# Ponseti Method of manipulation



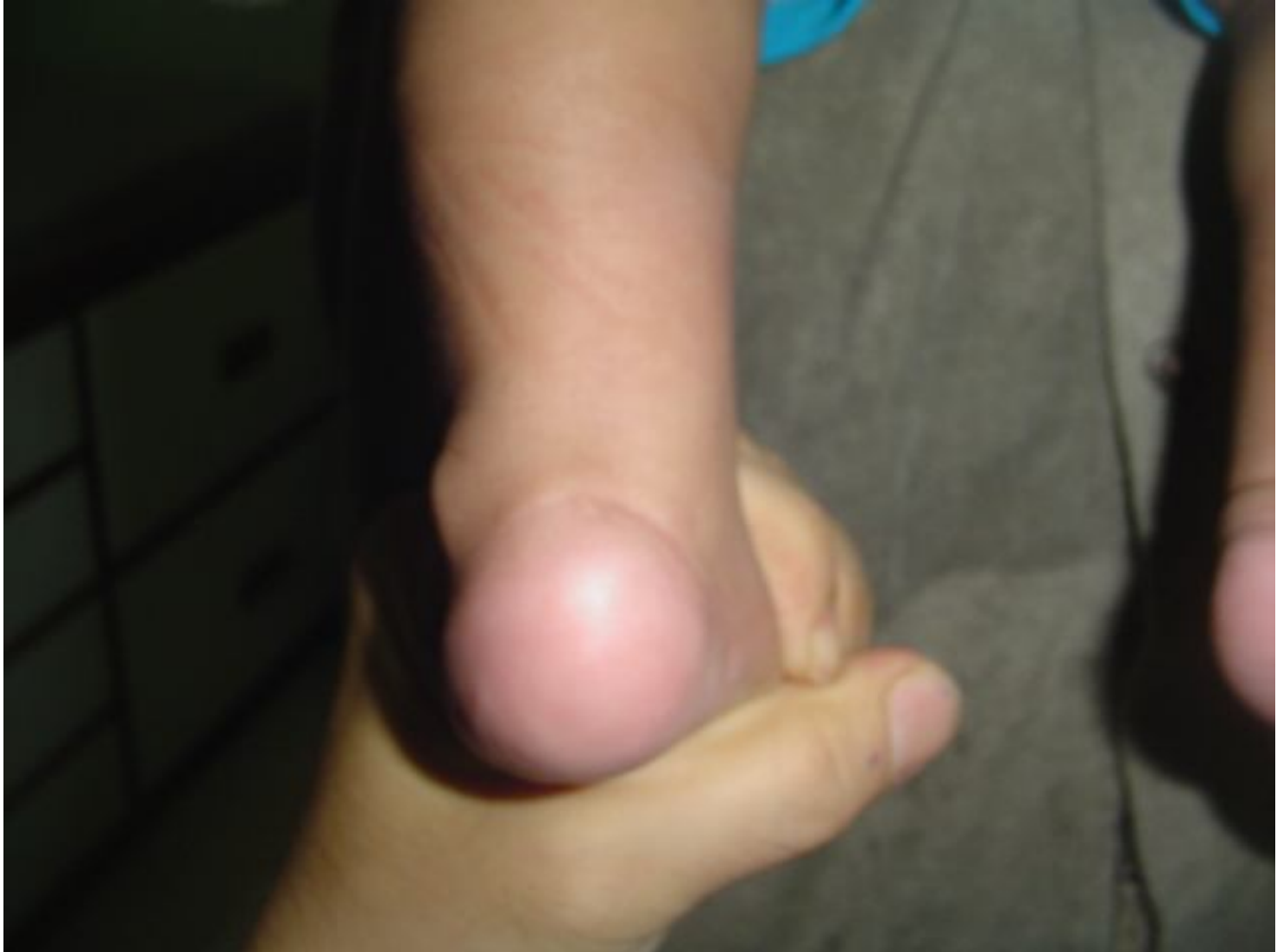# Photograph showing serial correction in plasters



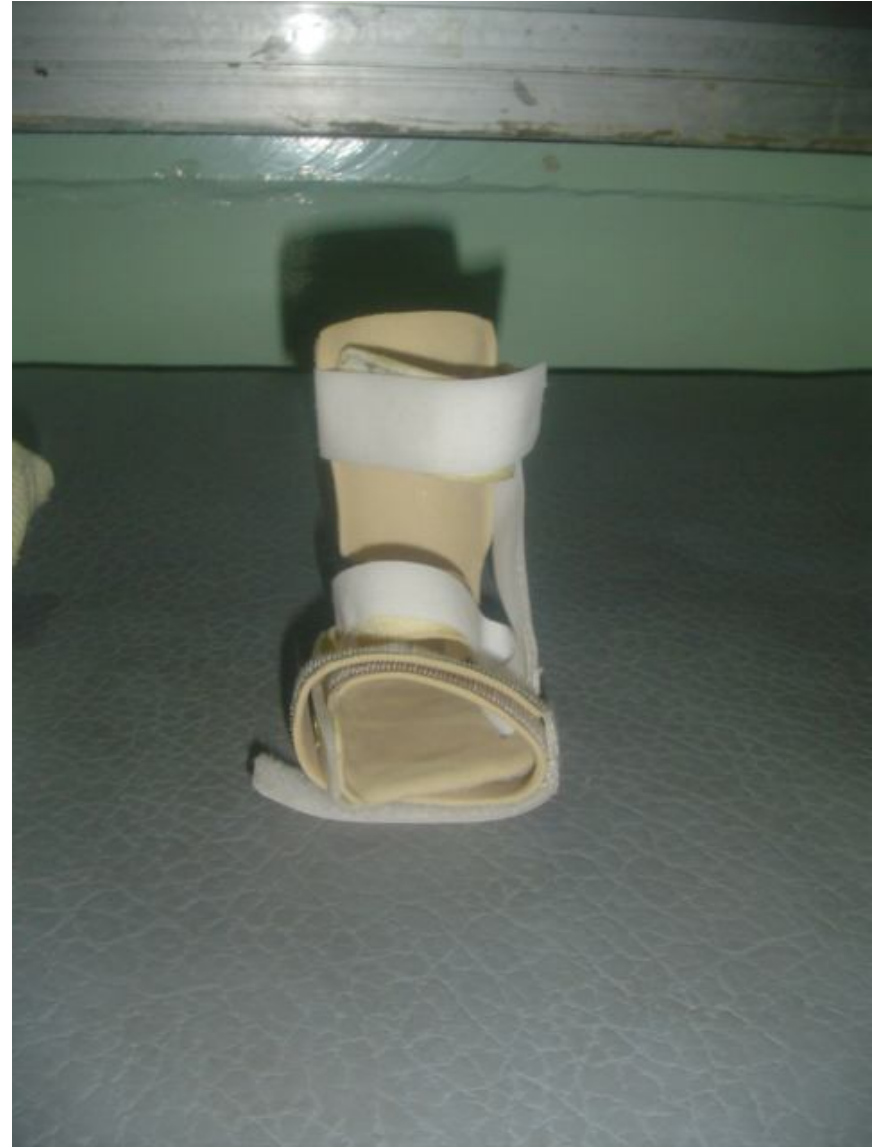
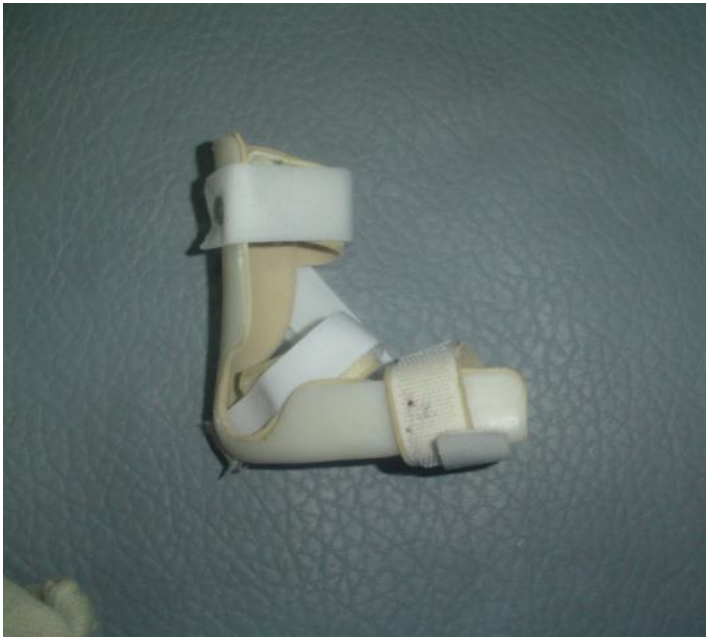# Photograph of final plaster



# Scar of tenotomy



# Splint

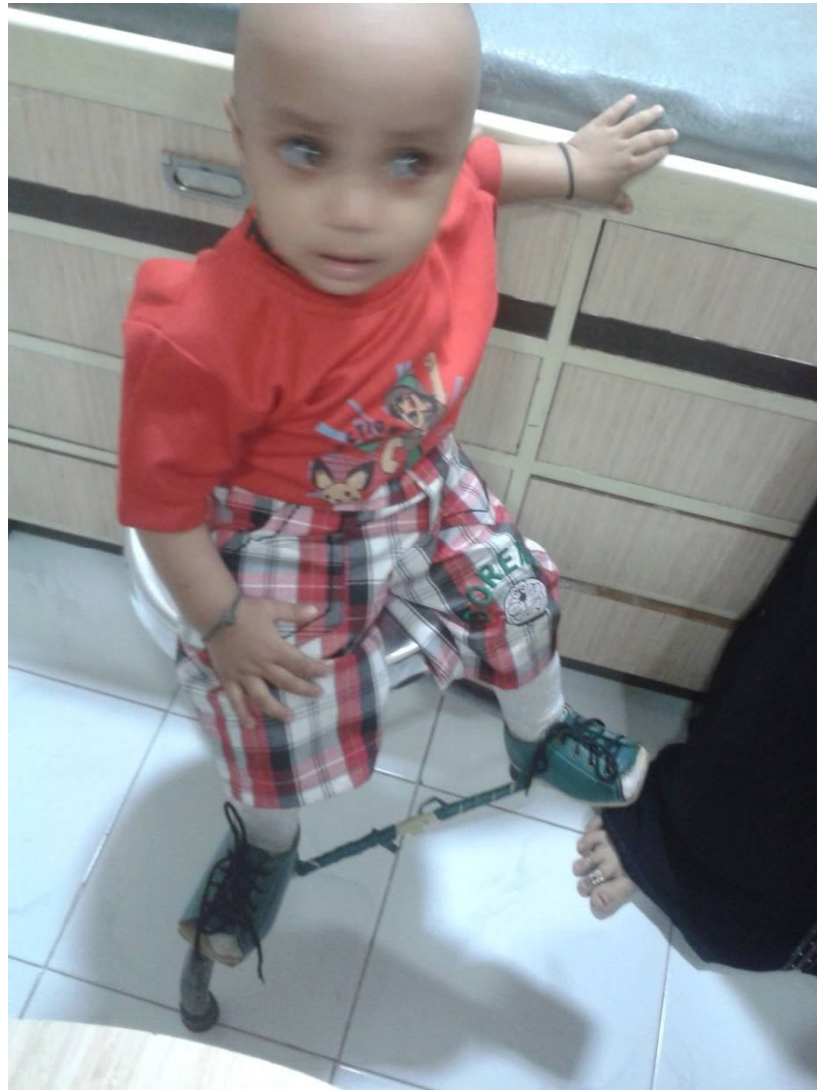



splint

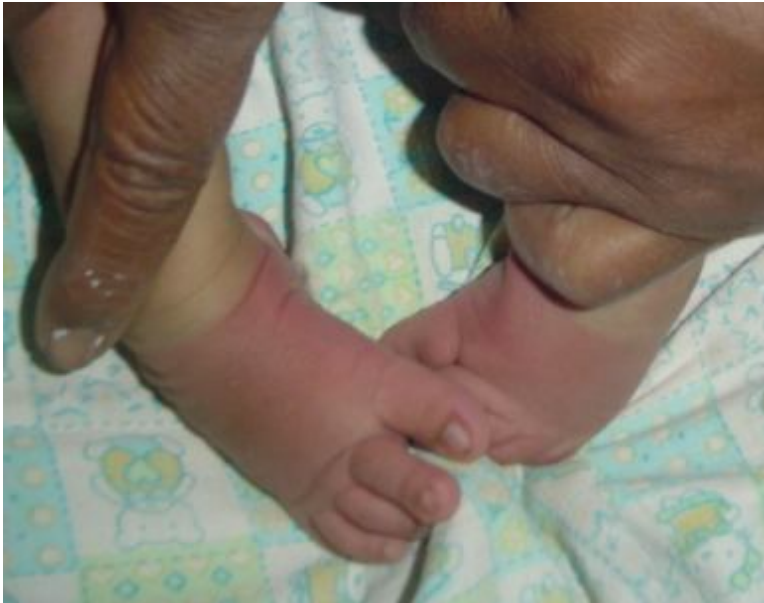

# Child standing wearing splint

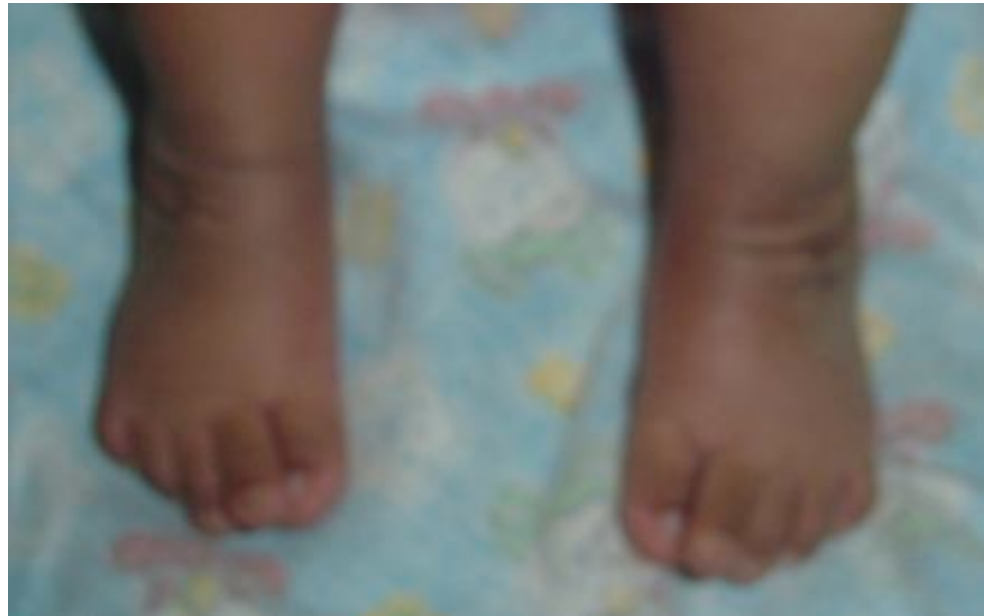

# Case of clubfoot treated by ponseti method

Pre Treatment



Post treatment

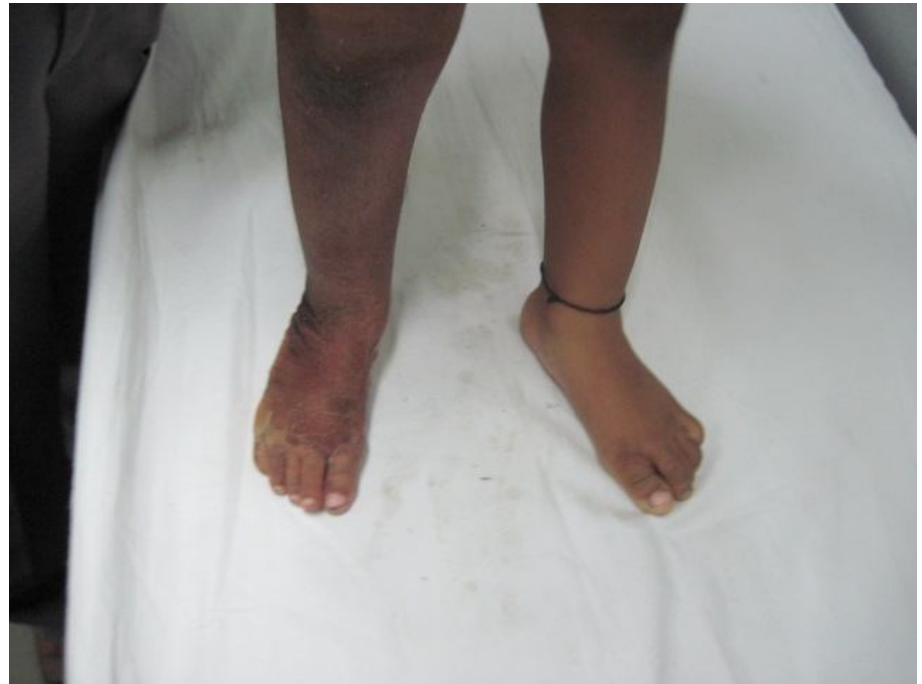
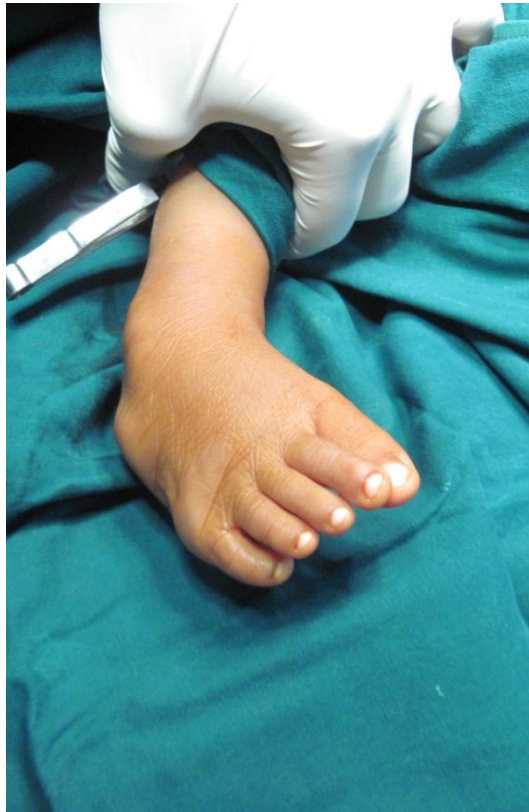


Same child at 4 years



# Postero medial release



# JESS fixator for correction of clubfoot

